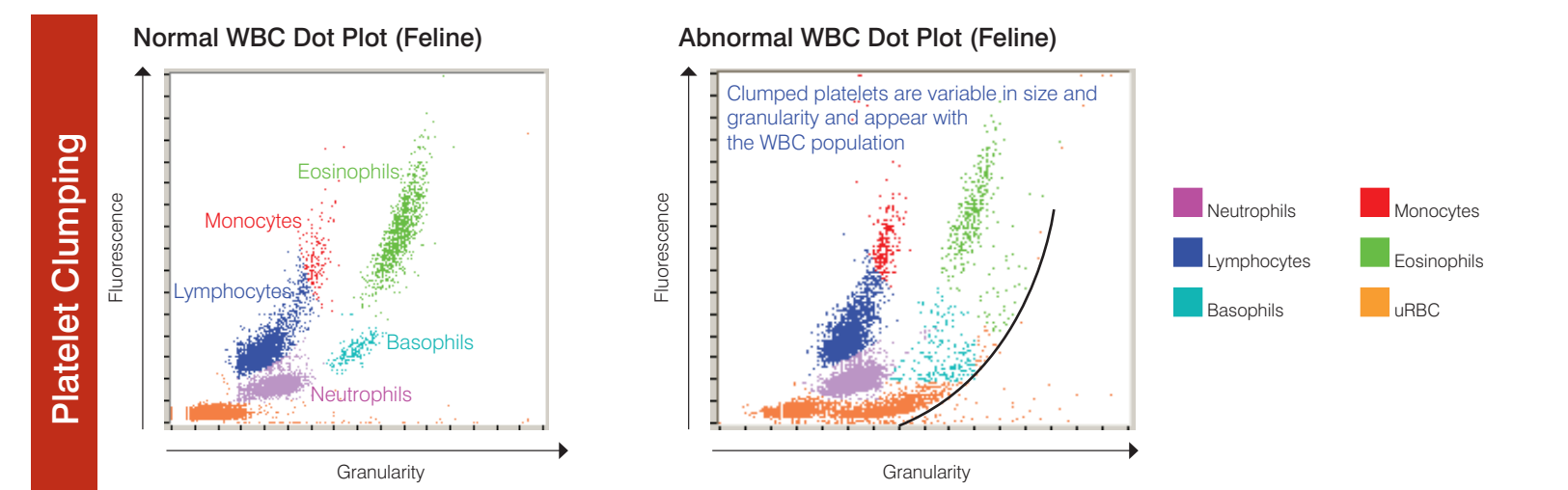
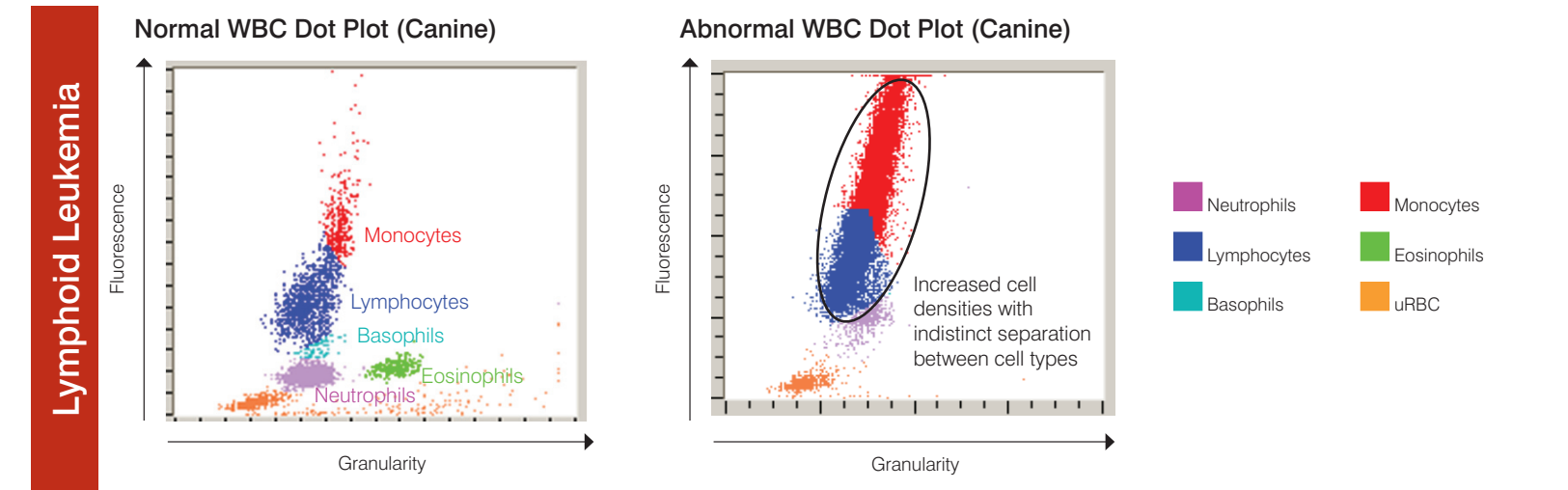
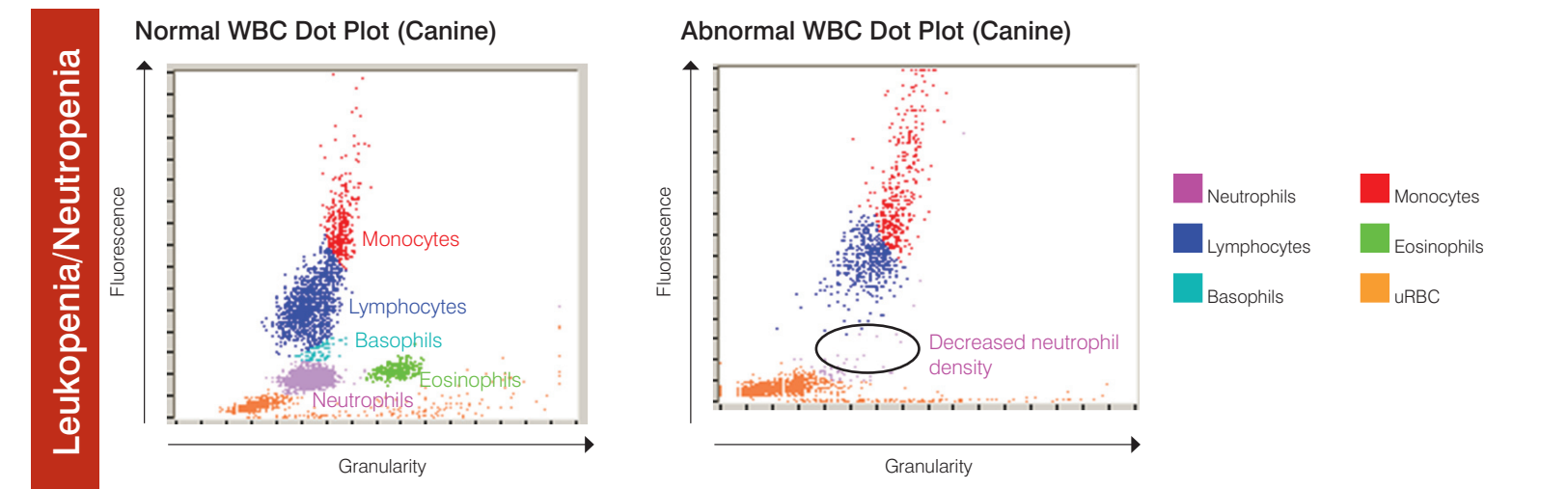
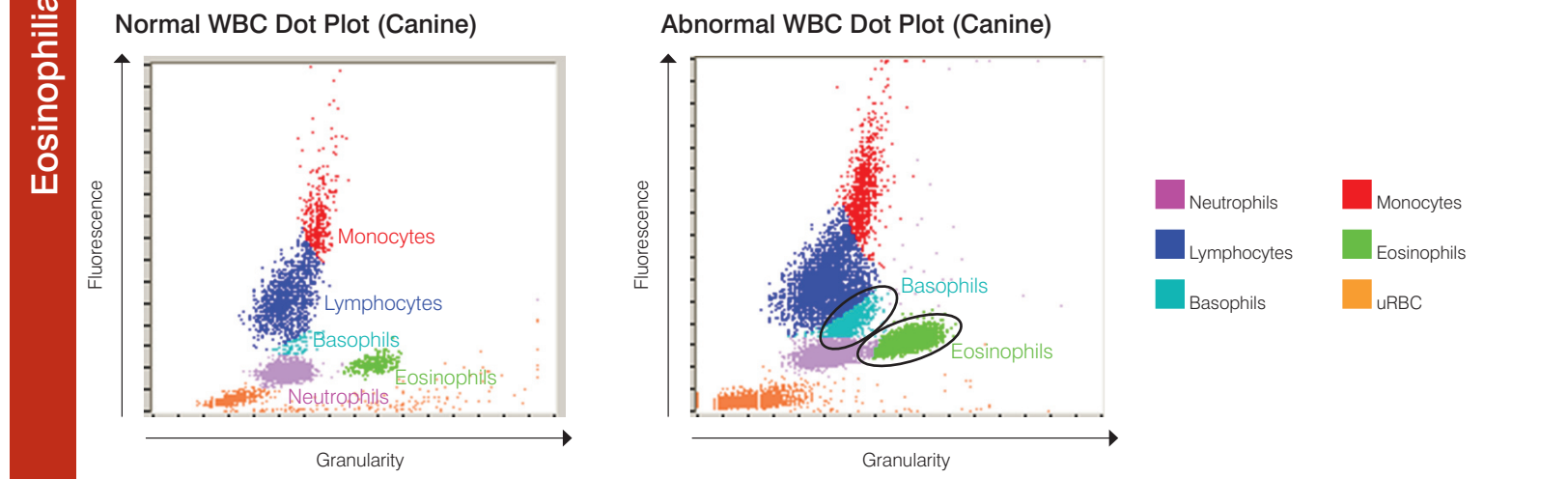
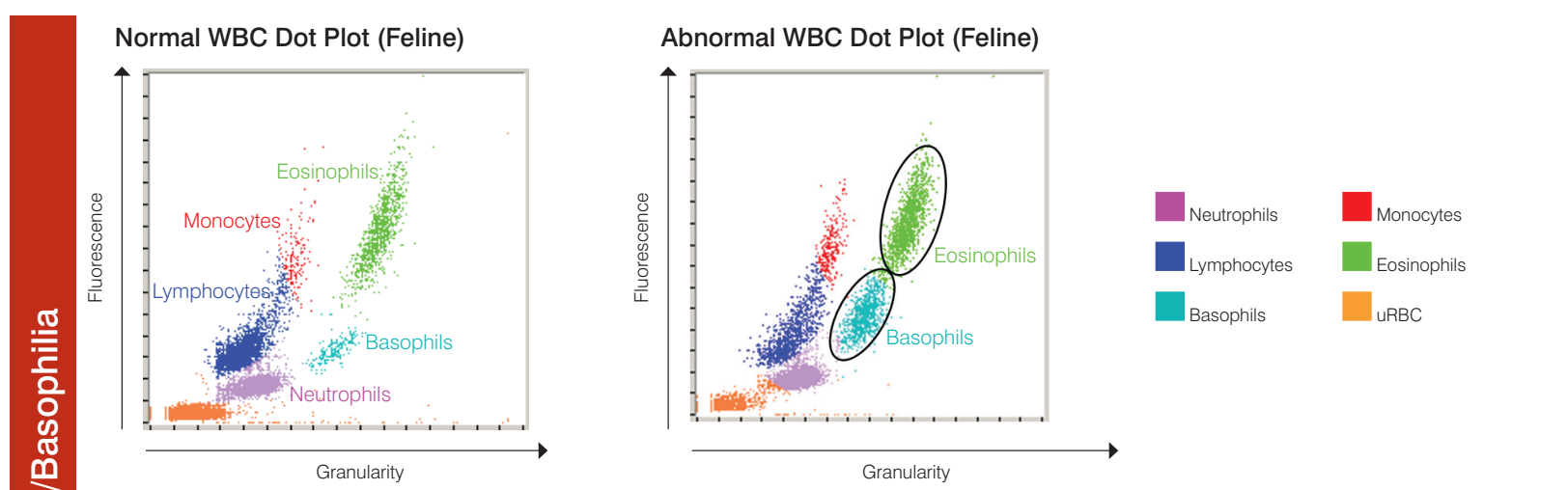
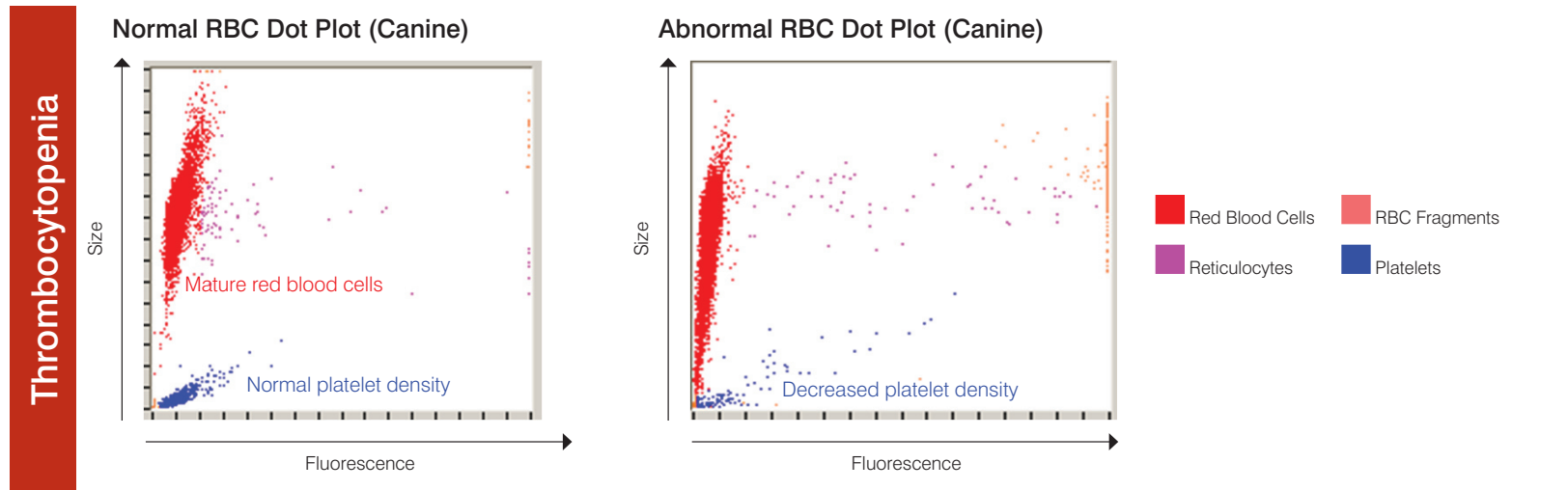
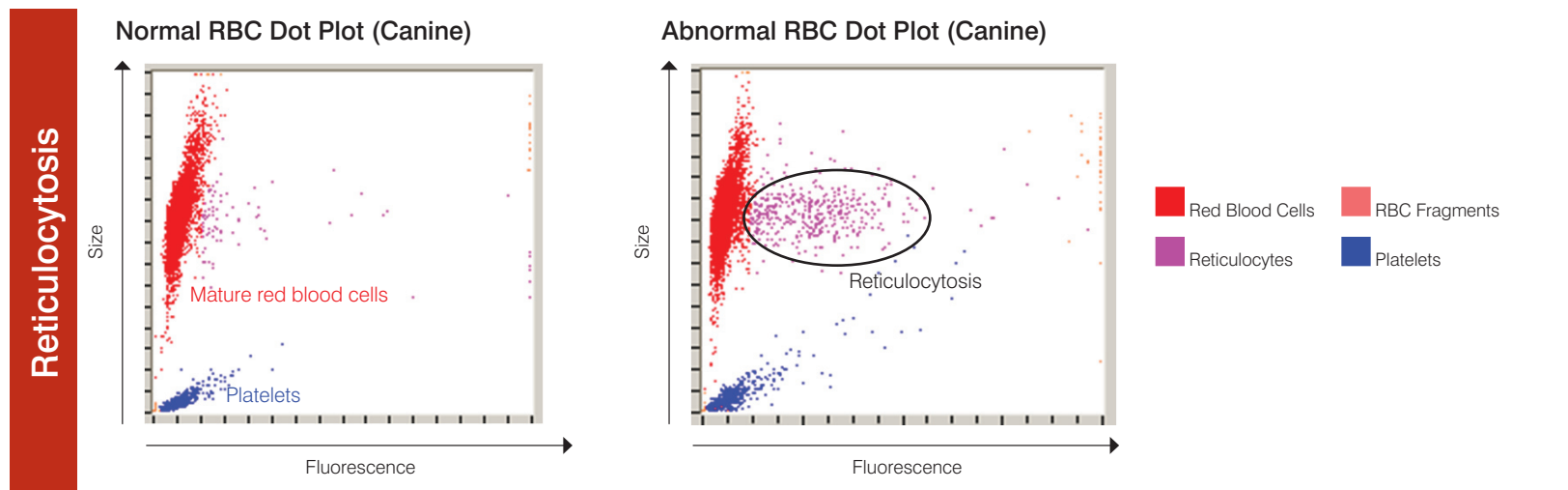


Interpreting IDEXX ProCyte Dx* Hematology Analyzer Dot Plots

Dot plots are a visual representation of the complete blood count (CBC); each dot represents a single cell. Dot plots are a critical element of the CBC, providing a snapshot of cellular morphology. This poster will help you identify various feline and canine disease states.



For more information about ProCyte Dx dot plots, contact IDEXX Technical Support.

IDEXX Technical Support
 Australia 1300 44 33 99
 U.S./Canada/Latin America 1-800-248-2483
 Europe 00800 1234 3399
 New Zealand 0800-102-084
 Asia 0800-291-018

Reticulocytosis

Reticulocytosis (increased number of reticulocytes) is the hallmark and most objective indicator of a regenerative anemia. Reticulocytosis without anemia may also be an indicator of resolving anemia or other occult disease processes. Reticulocytes are easily identified as the magenta dots to the right of the mature red blood cell population (red dots). The fluorescent dye binds to the residual reticulum, giving the reticulocytes fluorescence and a shift to the right when compared to the normal, nonfluorescing mature red blood cells. In the normal dot plot, there are few reticulocytes and their density is much less than that shown in the abnormal dot plot. Rapid review of the dot plot allows for quick validation of the reticulocyte count and therefore boosts confidence in results generated.

Thrombocytopenia

Thrombocytopenia can be a critical finding in a CBC, so rapid validation of results from the hematology analyzer is essential. In the red blood cell and platelet dot plots, severe thrombocytopenia is easily validated. In the normal patient dot plot, there are dense accumulations of blue dots representing individual platelet optical profiles. During severe thrombocytopenia, the density of the blue dots is dramatically reduced. Blood film microscopic review for possible platelet clumping is recommended for any case with a reported low-platelet count. Clumped platelets may cause a false low-platelet count and platelet events will not appear on the dot plots.

Eosinophilia/Basophilia

Recognition of increases in eosinophils (eosinophilia) and/or basophils (basophilia) is an important observation that directs diagnostic investigation toward specific diseases such as allergies, parasitic diseases and many others. Since they are of such value, rapid validation of reported eosinophilia and basophilia is quite important. In the dot plots, the eosinophils (green) are located to the right of the neutrophils in the dog and to the right of the monocytes in the cat. Basophils (teal) are located above the neutrophils in the dog and to the right of the lymphocytes in the cat. Different patterns are seen for different species because of their unique morphologic features. In the cases where a significant eosinophilia or basophilia is reported, the increased density of the eosinophil or basophil dot clouds makes the rapid confirmation of increased numbers of these cells simple.

Leukopenia/Neutropenia

Leukopenia or decreased total leukocyte numbers and in, particular, neutropenia or decreased neutrophil numbers often have high clinical significance related to overwhelming inflammatory disease and possible effects of chemotherapy; immediate knowledge of these situations is critical to the veterinarian. Marked decreases in leukocytes can be rapidly validated by examining dot plots. When an isolated cell type such as the neutrophil is significantly decreased, it is easily recognized because of the obvious lack of or dramatic decrease in density of the dot plot cloud associated with that particular leukocyte. In the case shown on the opposite side, there is a leukopenia characterized by a marked neutropenia: note the absence of the cloud of purple dots representing individual neutrophils in the sample.

Lymphoid Leukemia

Leukemia has multiple presentations: one of the most common is lymphoid leukemia either, as a result of progression of malignant lymphoma or primary lymphoid leukemia originating in the bone marrow. Most advanced hematology analyzers cannot accurately characterize these circulating malignant cells and, in many cases, the analyzers attempt cellular characterization but, because of difficulty in differentiating the various types of leukocytes, an “Abnormal WBC Distribution” message is reported to assure that there is follow-up evaluation of a blood film or submission to a reference laboratory for validation of the analyzer’s attempts. In normal WBC dot plots, there are distinctly identified clouds of different colored dots representing the different populations of leukocytes typically seen in the peripheral blood. However, in the dot plots of lymphoid leukemia patients, clear distinction between the different leukocyte clouds is not present—there is a continuum between different colored clouds. In these cases, the appropriate message code appears, indicating that the analyzer had difficulty in making accurate leukocyte characterizations and a blood film or submission to a reference laboratory is recommended.

Platelet Clumping

Platelet clumping is a common problem in veterinary medicine, especially with feline samples. Any time there is difficulty in sample collection resulting in a delay in filling the EDTA tube or delay in proper mixing, there is a potential for platelet clumping. There are different degrees of platelet clumping and most advanced analyzers have the capability of recognizing large platelet clumps. When identified, an appropriate message is relayed to the operator, along with qualification of selected results that could be impacted by the platelet clumping. The analyzer may still provide values; however, if there are qualifiers relayed or message codes reported, further evaluation and confirmation of the reported values is essential. A rapid review of the dot plots can also provide the operator with very quick validation that large platelet clumps are present. On the dot plots, large platelet clumps are recognized as a curvilinear path of dots extending from the population of unlysed (orange) cells paralleling the normal leukocyte clouds. In the dog, platelet clumping could impact eosinophil and neutrophil count. In the cat, basophil and eosinophil counts may be impacted. A rapid blood film review can allow for quick recognition of large platelet clumps and verification of results reported. If platelet clumps are reported or observed on the blood film, collection of a new sample for analysis is recommended.